

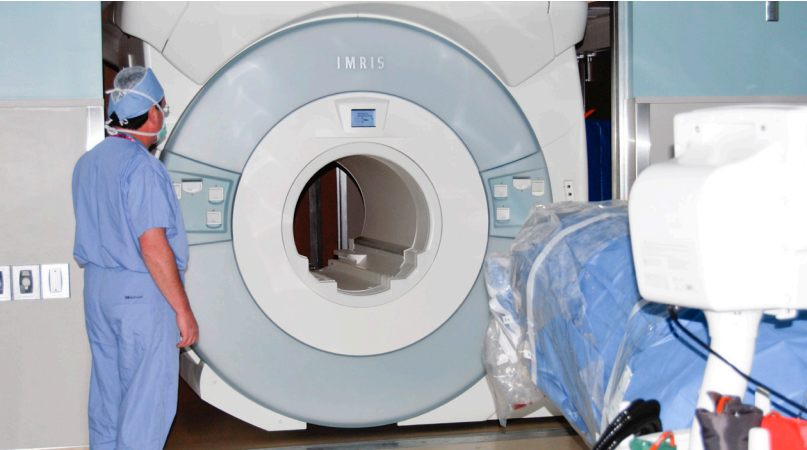**VISIUS** Surgical Theatre  
———— seeing is better

# Awake Craniotomy and Intraoperative MR Imaging

IMRIS Clinical Bulletin



# Washington University & Barnes-Jewish Hospital



Recently, the team at Washington University & Barnes-Jewish Hospital, St Louis MO has published a paper that provides compelling information about combining an awake craniotomy and intraoperative MR imaging (iMRI) in a single surgical case in a VISIUS Surgical Theatre™.

## Hospital Profile

- » Located in St Louis, Missouri, USA
- » Top 15 – U.S. News & World Report’s list of Best Hospitals for Neurology & Neurosurgery, 2011-2012
- » Prof. Ralph G. Dacey is the Chairman of the Department of Neurosurgery at Washington University School of Medicine and Chief of Neurosurgery at Barnes Jewish Hospital
- » Five dedicated neurosurgery operating rooms and a 20-bed neuro-intensive care unit (NICU)
- » VISIUS Surgical Theatre opened April 2008

## Published Paper

Use of Movable High-Field-Strength Intraoperative Magnetic Resonance Imaging With Awake Craniotomies for Resection of Gliomas: Preliminary Experience

Eric C. Leuthardt, MD*‡	Chris C. H. Lim, FRCS*§	Manish N. Shah, MD*
Keith M. Rich, MD*	Ralph G. Dacey, MD*	John A. Evans, RN*
Rene Tempelhoff, MD* ¶	Michael R. Chicoine, MD*	

Departments of \*Neurological Surgery and ‡Biomedical Engineering, Washington University, St Louis, Missouri; §Department of Neurosurgery, Beaumont Hospital Dublin, Ireland; ¶ Department of Anesthesia, Washington University School of Medicine, St. Louis, Missouri

*Neurosurgery* 69:194-206. 2011

# Surgical Techniques

In addition to the standard surgical techniques, the article describes seven additional steps required for an Awake Craniotomy:

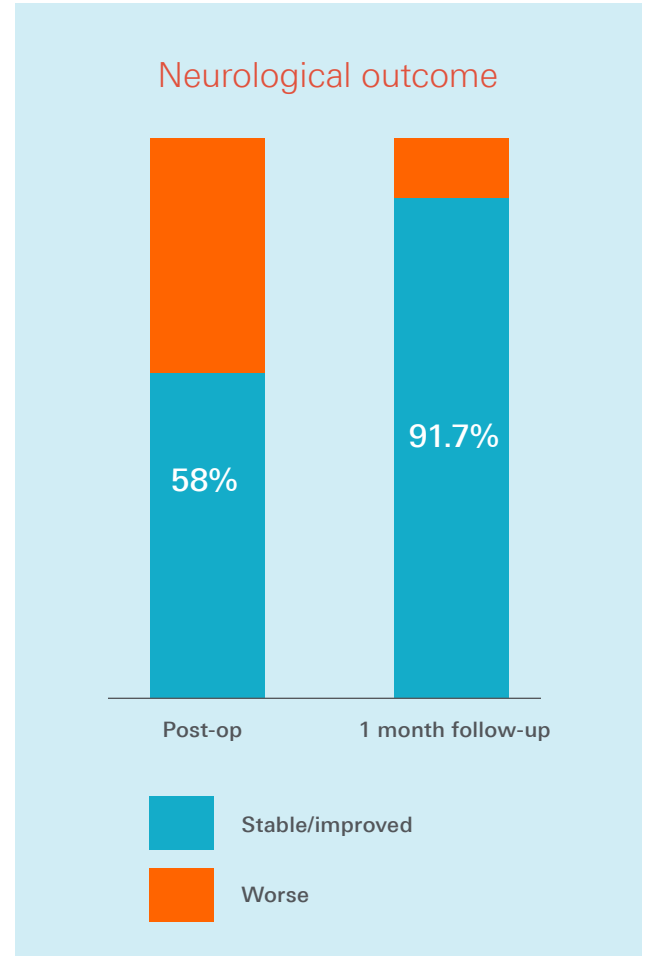
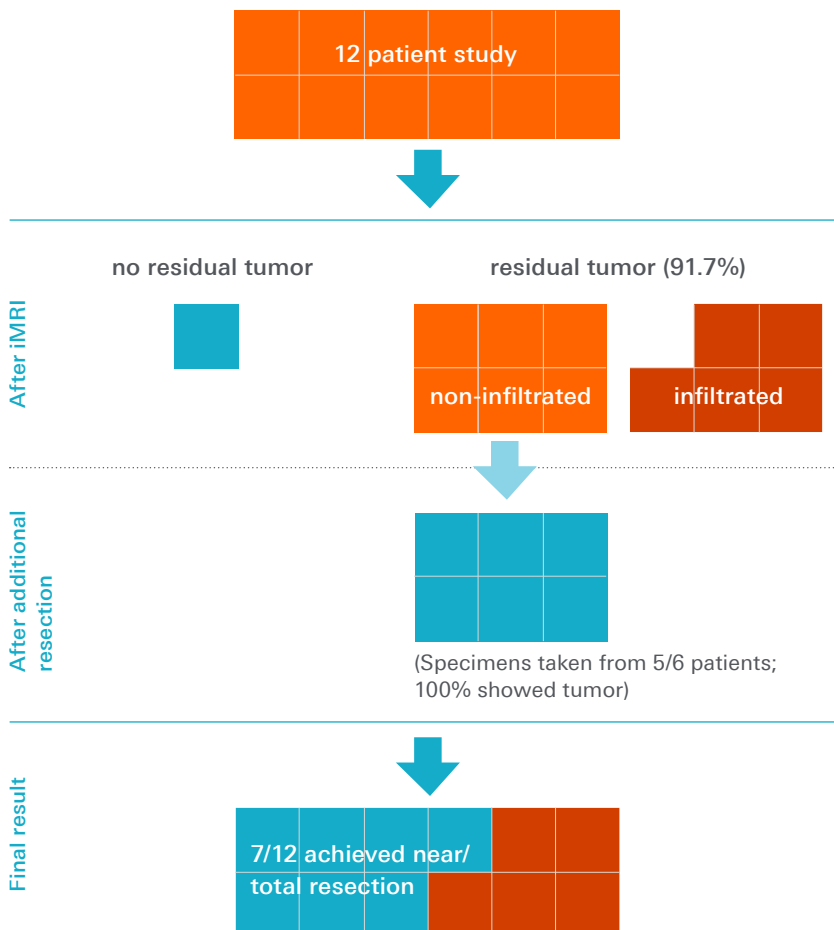
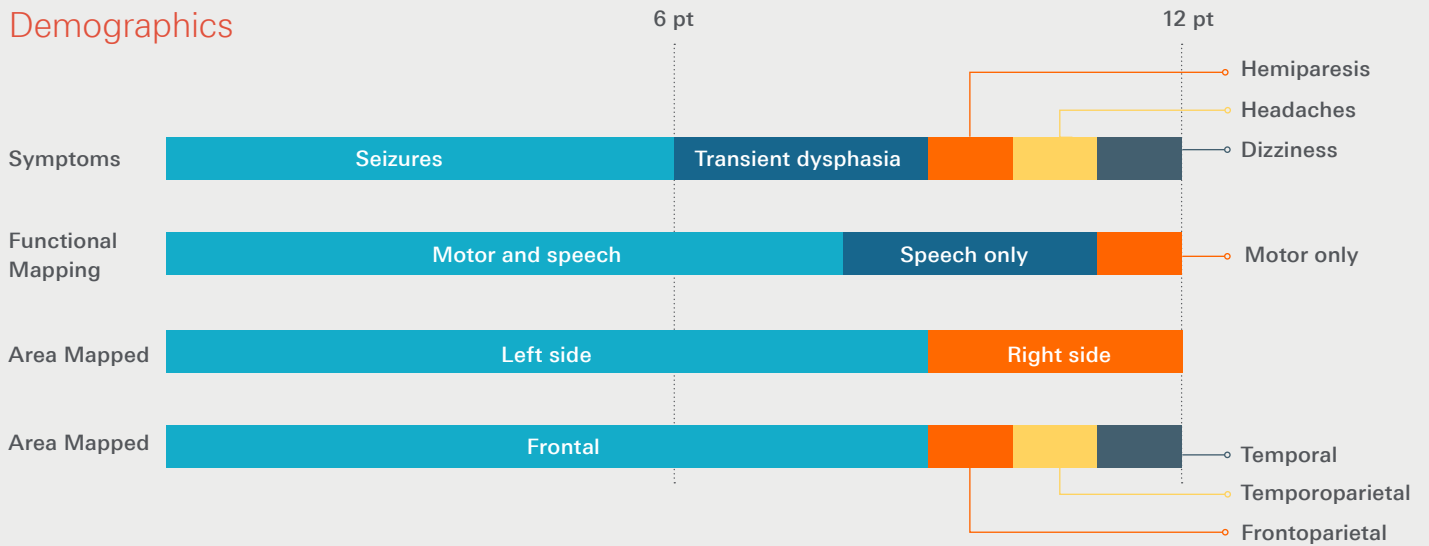
1. Start diuresis early to minimize brain swelling.
2. Bring patient into deep sedation and perform regional anesthetic scalp blocks once the patient is adequately secured to the operating table (beanbag and straps). Place the patient in a lateral recumbent position and place the table in an approximate 40° angle of the reverse Trendelenburg position.
3. Position and clamp the head, taking into consideration the position of the lesion for high-resolution iMRI.
4. Register patient to the frameless stereotactic navigation system.
5. Place the lower half of the 8-channel MRI coil.
6. Inject local anesthetic around the site of the planned incision.
7. Draping the patient, using a Mayo stand near the head to maintain the patient's line of vision for the awake portions of the procedure.

While these seven additional steps are being performed, all surgical instruments were counted by the surgical team before the iMRI was performed. After exposing the dura, the patient was awakened and standard motor and speech mapping were performed with electrocortical stimulation.

# Clinical Results

The study reviewed 12 patients from a prospective database. All patients had a Karnofsky Performance Status of greater than 70 at the time of surgery, and all patients underwent one iMRI session.

## Demographics



## Discussion/Conclusions

### Combining iMRI and awake craniotomy in a VISIUS Surgical Theatre

- » "...our initial small series demonstrates that these two techniques are complementary..."
- » "...our table has all of the degrees of freedom of a standard operating table, thus offering greater flexibility in terms of patient and table positioning."

### Tumor Resection

- » "We found that it is feasible and practical and offers potential to improve the extent of tumor resection."
- » "This technique offers potential to improve the extent of the tumor resection near eloquent areas of the brain..."

### Patient Safety

- » "...the patient remains secured to the operating table, which remains fixed to the floor on its pedestal, and the iMRI device moves to the patient, which we believe offers greater patient safety..."



#### Correspondence:

Michael R. Chicoine, MD  
Associate Professor,  
Department of Neurosurgery,  
Washington University School of  
Medicine  
Campus Box 8057  
660 S. Euclid Avenue  
St. Louis, MO 63110  
Email: chicoinem@wudosis.wustl.edu

## Use of Movable High-Field-Strength Intraoperative Magnetic Resonance Imaging With Awake Craniotomies for Resection of Gliomas: Preliminary Experience

**BACKGROUND:** Awake craniotomy with electrocortical mapping and intraoperative magnetic resonance imaging (iMRI) are established techniques for maximizing tumor resection and preserving function, but there has been little experience combining these methodologies.

**OBJECTIVE:** To report our experience of combining awake craniotomy and iMRI with a 1.5-T movable iMRI for resection of gliomas in close proximity to eloquent cortex.

**METHODS:** Twelve patients (9 male and 3 female patients; age, 32-60 years; mean, 41 years) undergoing awake craniotomy and iMRI for glioma resections were identified from a prospective database. Assessments were made of how these 2 modalities were integrated and what impact this strategy had on safety, surgical decision making, workflow, operative time, extent of tumor resection, and outcome.

**RESULTS:** Twelve craniotomies were safely performed in an operating room equipped with a movable 1.5-T iMRI. The extent of resection was limited because of proximity to eloquent areas in 5 cases: language areas in 3 patients and motor areas in 2 patients. Additional tumor was identified and resected after iMRI in 6 patients. Average operating room time was 7.9 hours (range, 5.9-9.7 hours). Compared with preoperative neurological function, immediate postoperative function was stable/improved in 7 and worse in 5; after 30 days, it was stable/improved in 11 and worse in 1.

**CONCLUSION:** Awake craniotomy and iMRI with a movable high-field-strength device can be performed safely to maximize resection of tumors near eloquent language areas.

**KEY WORDS:** Awake craniotomy, Glioma, iMRI, Intraoperative magnetic resonance imaging, Movable high-field-strength iMRI

## Suggested Readings:

1. Nabavi A, Goebel S, Doerner L, Warneke N, Ulmer S, Mehdorn M. Awake craniotomy and intraoperative magnetic resonance imaging: patient selection, preparation, and technique. *Top Magn Reson Imaging*. 2008 Jan;19(4):191-196.
2. Weingarten DM, Asthagiri AR, Butman JA, et al. Cortical mapping and frameless stereotactic navigation in the high-field intraoperative magnetic resonance imaging suite. *J Neurosurg*. 2009;111(6):1185-1190.
3. Parney IF, Goerss SJ, McGee K, Huston J, Perkins WJ, Meyer FB. Awake craniotomy, electrophysiological mapping, and tumor resection with high-field intra-operative MRI. *World Neurosurg*. 2010;73(5):547-551.
4. Goebel S, Nabavi A, Schubert S, Mehdorn HM. Patient perception of combined awake brain tumour surgery and intraoperative 1.5-T-MRI: the Kiel experience. *Neurosurgery*. 2010;67(3):594-600.
5. Peruzzi P, Puente E., Bergese S, Chiocca EA. Intraoperative MRI (ioMRI) in the setting of awake craniotomies for supratentorial glioma resection. *Acta Neurochir Suppl*. 2011;109:43-8.
6. Leuthardt, EC, Lim CCS, Shah MN, Evans, JA, Rich KM, Dacey RG, Tempelhoff R, Chicoine MR: Utilization of Movable High Field Strength Intraoperative Magnetic Resonance Imaging with Awake Craniotomies for Resection of Gliomas. A Preliminary Experience, *Neurosurgery*. 2011;69(1):194-206.
7. Chicoine MR, Lim CCH, Evans JA, Singla A, Zipfel GJ, Rich KM, Dowling JL, Leonard JR, Smyth MD, Santiago P, Leuthardt EC, Limbrick DD, Dacey RG : Implementation and Preliminary Clinical Experience with the Use of Ceiling Mounted Mobile High Field Intraoperative Magnetic Resonance Imaging Between 2 Operating Rooms, *ACTA Neurochirurgica suppl*. 2011;109:97-102.
8. Lu J, Wu J, Yao C, et al. Awake language mapping and 3-Tesla intraoperative MRI-guided volumetric resection for gliomas in language areas. *J Clin Neurosci*. 2013 Sept;20(9):1280-7.